



PROFESSIONAL PATHOLOGY SERVICES, PC
DERMATOPATHOLOGY DIVISION
Lawrence E. Klein, MD
One Science Court, Suite 200
Columbia, SC 29203
(803) 252-1913
Dermatopathology Report

Patient Name: **TEST, BARBARA** Med. Rec. #: 877893-BT
DOB/Age: 4/4/1967 (Age: 39)/F
Soc. Sec. #: 234-56-7891
Client: Test Client
Physician: Test Doctor, MD

Accession #: **D06-8**
Date of Service: 7/26/2006
Date Received: 7/26/2006
Date Reported: 7/26/2006

CLINICAL DATA:

- A. LEFT TEMPLE: LENTIGO VS SK R/O ATYPIA AKS
- B. LEFT ANTERIOR SHOULDER: LICHENOID KERATOSIS R/O BOWEN'S
- C. RIGHT ANT LEG: INFL SK R/O SCC

DIAGNOSIS

- A. LEFT TEMPLE: **RETICULATED SEBORRHEIC KERATOSIS (702.19) CPT88305**
- B. LEFT ANTERIOR SHOULDER: **SEBORRHEIC KERATOSIS WITH LICHENOID INFLAMMATION (702.11) CPT88305**
- C. RIGHT ANT LEG: **ATYPICAL SQUAMOUS HYPERPLASIA, SEE DESCRIPTION (238.2) CPT88305**

Electronically Signed Out By System Manager II
Staff Pathologist, M.D.

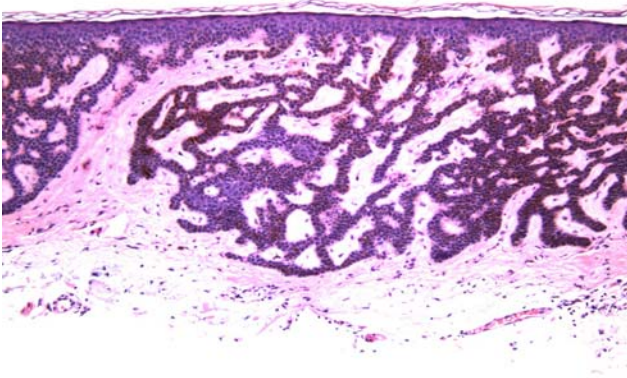
sk/7/26/2006

GROSS DESCRIPTION:

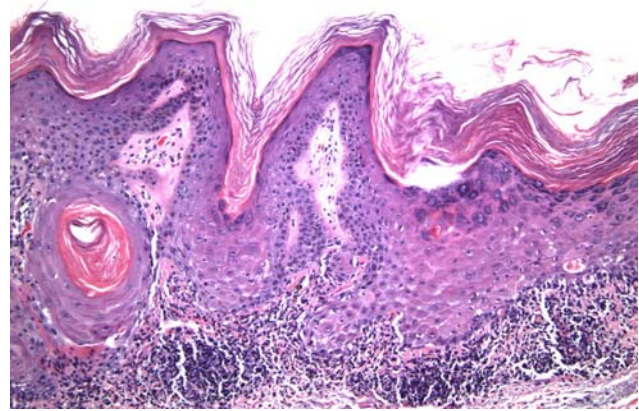
- A. LEFT TEMPLE: Received skin fragment(s) in formalin fixative, bisected and submitted in toto, measuring .5 cm.
- B. LEFT ANTERIOR SHOULDER: Fragment(s) of skin received in formalin, trisected and submitted in toto, measuring .8 cm.
- C. RIGHT ANT LEG: Received skin fragment(s) in formalin fixative, bisected and submitted in toto, measuring .7 cm.

MICROSCOPIC DESCRIPTION:

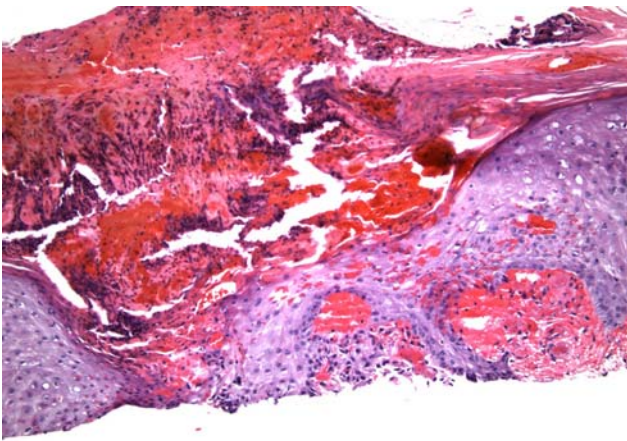
- A. LEFT TEMPLE: There is basaloid hyperplasia of the epidermis in a reticulated pattern. In the dermis there is chronic inflammation.
- B. LEFT ANTERIOR SHOULDER: There is papillomatosis and irregular hyperplasia of the epidermis. In the dermis there is a lichenoid inflammatory infiltrate composed predominantly of mononuclear cells.
- C. RIGHT ANT LEG: There is hyperkeratosis, hemorrhagic inflammatory crusting and irregular epidermal hyperplasia. Keratinocytic atypia is present. This lesion extends to the base of the specimen. The differential diagnosis for this lesion includes an atypical reactive keratosis and squamous cell carcinoma. Deeper biopsy sampling may be appropriate if the latter diagnosis remains of clinical concern.



Speciman A



Speciman B



Speciman C