



**PROFESSIONAL PATHOLOGY SERVICES, PC
SURGICAL PATHOLOGY DIVISION**

One Science Court, Suite 200
Columbia, SC 29203
1-866-252-1913

Surgical Pathology Report

Patient Name: **TESTING, ANN** Med. Rec. #: 87837487AT
DOB/Age: 5/24/1963 (Age: 43)/F
Soc. Sec. #: 135-46-5789
Client: Test Client
Physician: Test Doctor, MD
Copy To:

Accession #: **R06-12**
Date of Service: 7/25/2006
Date Received: 7/26/2006
Date Reported: 7/26/2006

CLINICAL DATA:

A. ENDOMETRIAL BX: ABNORMAL UTERINE BLEEDING

DIAGNOSIS

A. ENDOMETRIUM, BIOPSY:

- BENIGN ENDOMETRIUM WITH PREMATURE GLAND AND STROMAL BREAKDOWN.
- INFLAMED ENDOCERVICAL POLYP

Electronically Signed Out By System Manager II
Staff Pathologist, M.D.

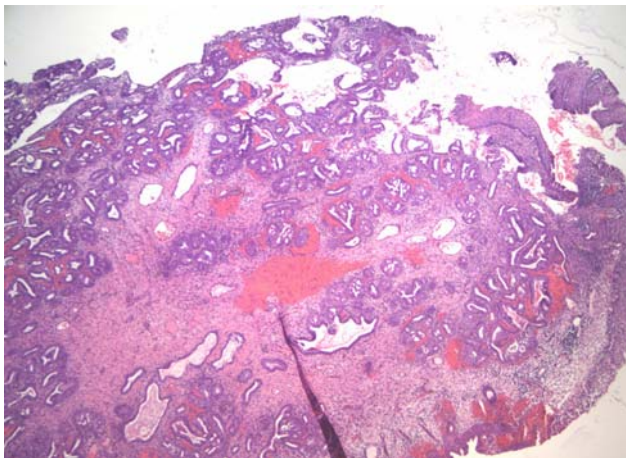
sk/7/26/2006

GROSS DESCRIPTION:

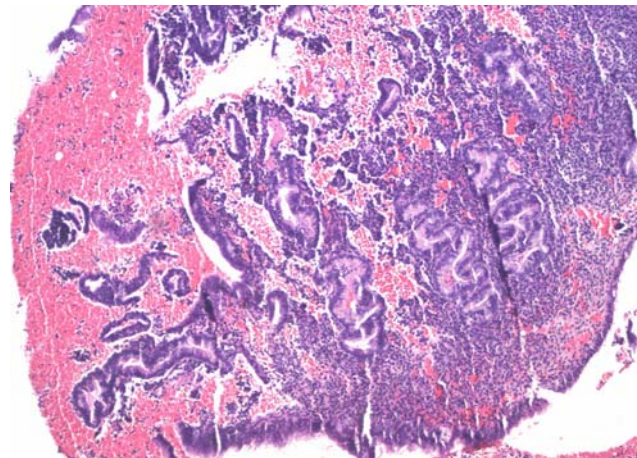
A. Received in formalin is a 1.8 x 1.5 x 1.0 cm aggregate of hemorrhagic tissue, submitted in toto.

MICROSCOPIC DESCRIPTION:

A. Endometrial biopsy is adequate for evaluation and demonstrates numerous fragmenting portions of endometrial glands and stroma. There is a mixture of inactive glands with exhausted secretory phase change and mixed with areas of stromal collapse and fibrin thrombi. Also noted is an endocervical type polyp with metaplastic squamous change and mixed inflammation. No evidence of endometrial hyperplasia, neoplasia, or endometritis is seen.



Endocervical Polyp



Endometrium