



**PROFESSIONAL PATHOLOGY SERVICES, PC**  
**DERMATOPATHOLOGY DIVISION**  
Lawrence E. Klein, MD  
One Science Court, Suite 200  
Columbia, SC 29203  
(803) 252-1913  
**Dermatopathology Report**

Patient Name: **TEST, NORMAL** Med. Rec. #: 9898908  
DOB/Age: 5/3/1965 (Age: 41)/F  
Soc. Sec. #: 938-49-0982  
Client: Test Client  
Physician: Test Doctor, MD

Accession #: **D06-9**  
Date of Service: 7/26/2006  
Date Received: 7/26/2006  
Date Reported: 8/4/2006

**CLINICAL DATA:**

- A. NOSE: ISK
- B. RIGHT CHEEK: BCC

**DIAGNOSIS**

- A. NOSE: **FIBROUS PAPULE OR ANGIOFIBROMA (216.3) CPT88305**
- B. RIGHT CHEEK: **BASAL CELL CARCINOMA (173.3) CPT88305**

\*\*\*Electronically Signed Out By System Manager\*\*\*  
Lawrence E. Klein, M.D.

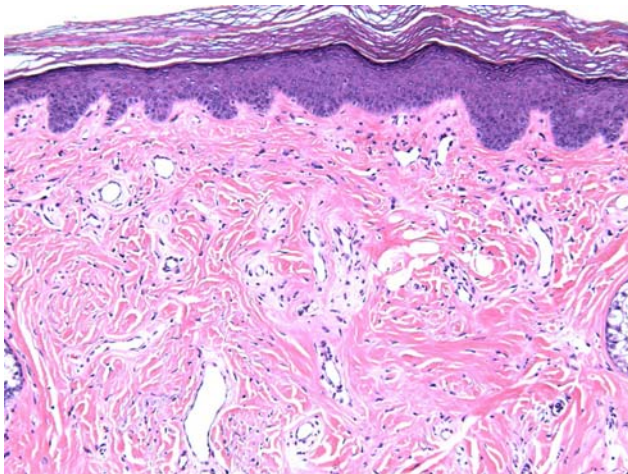
sk/7/26/2006

**GROSS DESCRIPTION:**

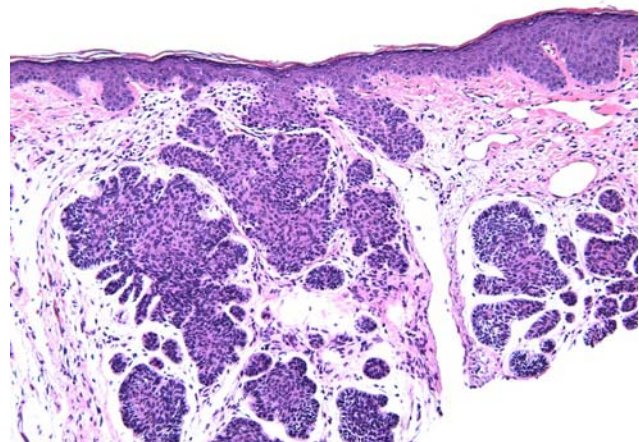
- A. NOSE: Received skin fragment(s) in formalin fixative, bisected and submitted in toto, measuring .5 cm.
- B. RIGHT CHEEK: Received skin fragment(s) in formalin fixative, bisected and submitted in toto, measuring .8 cm.

**MICROSCOPIC DESCRIPTION:**

- A. NOSE: In the dermis there is fibrosis, slight vascular dilatation and a proliferation of spindle and stellate shaped cells. These findings are consistent with a fibrous papule or angiofibroma.
- B. RIGHT CHEEK: Clusters of atypical basaloid cells are present in the dermis and extend focally to the base of the specimen.



Specimen A



Specimen B