



**PROFESSIONAL PATHOLOGY SERVICES, PC  
SURGICAL PATHOLOGY DIVISION**

One Science Court, Suite 200  
Columbia, SC 29203  
1-866-252-1913

**Surgical Pathology Report**

Patient Name: **TEST, JOAN**  
DOB/Age: 5/14/1974 (Age: 32)/F  
Soc. Sec. #: 222-22-2222  
Client: Test Client  
Physician: Test Doctor, MD  
Copy To: Sample Physician, MD

Accession #: **R06-13**  
Date of Service: 7/27/2006  
Date Received: 7/27/2006  
Date Reported: 8/7/2006

**CLINICAL DATA:**

A. CORE BIOPSY RT BREAST:

**DIAGNOSIS**

A. RIGHT BREAST, CORE NEEDLE BIOPSY:  
- **INFILTRATING DUCTAL CARCINOMA**

**NOTE:**

Needle cores show an infiltrating ductal carcinoma of apparent low to intermediate grade. Definitive grading requires examination of the completely excised lesion.

\*\*\*Electronically Signed Out By System Manager\*\*\*  
Staff Pathologist, M.D.

sk/7/27/2006

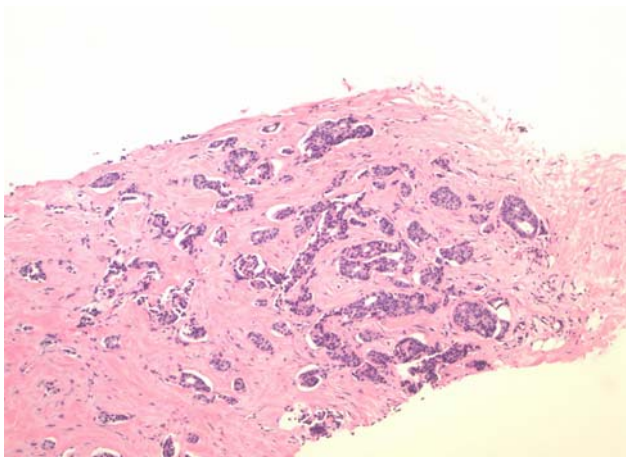
**GROSS DESCRIPTION:**

A. Received four tissue core(s) in formalin, and submitted in toto and measuring 0.6-1.5 cm.

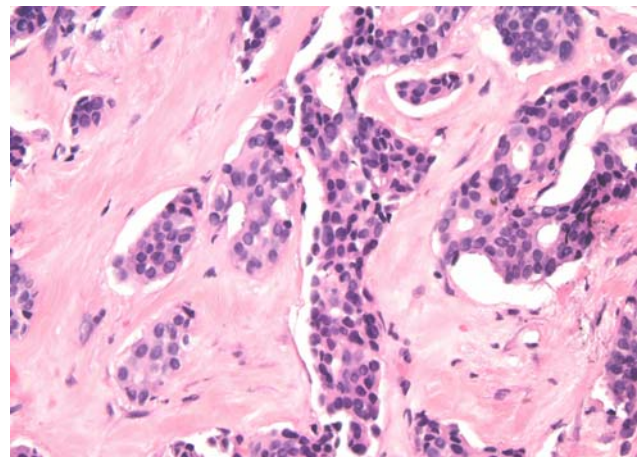
**MICROSCOPIC DESCRIPTION:**

A. Breast core biopsy shows a desmoplastic fibrous background infiltrated by tumor present as cords and tubular arrangements of cuboidal cells with G2 nuclei. No in-situ component is identified in this needle biopsy.

**Consultant:** Dr. Pappy Smear.



Tumor Infiltrate



(detail)